

## Original Paper

# Discrimination between red blood cell and platelet components of blood clots by MR microscopy

Jernej Vidmar<sup>1</sup>, Igor Serša<sup>1</sup>, Eduard Kralj<sup>2</sup>, Gregor Tratar<sup>3</sup> and Aleš Blinc<sup>3</sup>

- (1) Jožef Stefan Institute, Jamova 39, Ljubljana, 1000, Slovenia
- (2) Institute of Forensic Medicine, University of Ljubljana Medical School, Ljubljana, 1000, Slovenia
- (3) Department of Vascular Diseases, University of Ljubljana Medical Centre, Ljubljana, 1000, Slovenia

**Jernej Vidmar**

**Email:** jernej.vidmar@ijs.si

**Received:** 5 March 2008

**Accepted:** 11 April 2008

**Published online:** 1 May 2008

## Abstract

Magnetic resonance imaging (MRI) of pulmonary emboli obtained *ex vivo*, verified by immunohistochemistry, showed that platelet layers display brighter signal intensity than areas containing predominantly red blood cells (RBC) in  $T_1$ -weighted MRI. These results were surprising since platelets do not contain paramagnetic haemoglobin that would enhance magnetic relaxation. Our assumption was that the fibrin meshwork areas with entrapped RBC retain abundant extracellular space filled with serum, whereas platelets regroup into tight aggregates lacking serum, essentially mimicking solid tissue structure, rich with cellular proteins that enhance  $T_1$ -relaxation. Our hypothesis was examined by MRI and NMR relaxometry of *in vitro* RBC suspensions and sedimented platelets, as well as by MRI of model clots and pulmonary emboli obtained *ex vivo*. Pure sedimented platelets exhibited shorter proton spin lattice relaxation times ( $T_1 = 874 \pm 310$  ms) than those of venous blood of a healthy male with

40% haematocrit ( $T_1 = 1277 \pm 66$  ms).  $T_1$ -values of RBC samples containing high haematocrit ( $\geq 80\%$ ) resembled  $T_1$  of platelet samples. In  $T_1$ -weighted spin-echo MRI echo time and repetition time (TE/TR = 10/120 ms) the ratio of signal intensities between a non-retracted whole blood clot (with a haematocrit of 35%) and a pure platelet clot was 3.0, and the ratio between a retracted whole blood clot with an estimated haematocrit of about 58% and a pure platelet clot was 2.6. We conclude that  $T_1$ -weighted MRI can discriminate between platelet layers of thrombi and RBC-rich areas of thrombi that are not compacted to a haematocrit level of  $\geq 80\%$ .

**Keywords** MR microscopy – Pulmonary emboli – In vitro clot – Platelet aggregates

### **Abbreviations**

***RBC***

Red blood cell

***Ht***

Haematocrit

***MR***

Magnetic resonance

***MRI***

Magnetic resonance imaging

Regional Biophysics Conference of the National Biophysical Societies of Austria, Croatia, Hungary, Italy, Serbia, and Slovenia.

---

## **Introduction**

Blood clots are an important component of cardiovascular thrombosis and are associated with cardiovascular dysfunction, ischaemic cerebrovascular stroke or acute pulmonary embolism. Generation of a blood clot requires thrombin-mediated conversion of fibrinogen to fibrin, resulting in the creation of linear polymers that form by end-to-end and side-to-side associations, and bind to platelets. While the presence of platelet aggregates and fibrin meshwork is desirable in haemostasis, large platelet areas in fibrin clots retard thrombolysis (Weisel 2007). Several noninvasive methods, including magnetic resonance imaging (MRI), have been used for assessing thrombus structure in order to predict the response to thrombolytic treatment (Francis and Totterman 1995; Kozak et al. 2005). Two independent groups have recently found that platelet aggregates show a significantly brighter signal than red cell-rich parts of thrombi in  $T_1$ -weighted MRI (Tratar et al. 2007; Viereck et al. 2005).

In our previous experiments, high resolution 3-dimensional  $T_1$ -weighted spin-echo MRI of ex vivo pulmonary emboli consistently showed well-defined layers of bright signal in emboli that had been immunohistochemically identified as platelets (Tratar et al. 2007). The finding that platelet aggregates have brighter signal intensity in  $T_1$ -weighted MRI is counterintuitive, since platelets do not contain paramagnetic haemoglobin. Deoxyhaemoglobin in red blood cells (RBC) acts as a paramagnetic centre, while oxyhaemoglobin is diamagnetic (Gupta 1987). One would expect that the proton spin lattice relaxation time  $T_1$  would be shorter in areas rich with RBC than in areas rich with platelets, and that the signal intensity in  $T_1$ -weighted MR images would be greater in red clots than in white clots. In order to explain such a discrepancy, we hypothesised that the areas in thrombi rich with RBC retain abundant extracellular space filled with serum. On the other hand, activated platelets link with each other via glycoprotein receptors (GPIIb/IIIa) and fibrinogen (Ruggeri 1997; Savage et al. 2001; Stump and Mann 1988) forming tightly bonded aggregates, which resemble “solid tissue” where cellular proteins enhance magnetic relaxation.

In order to study the mechanism underlying the MRI appearance of platelets, we measured the proton relaxation times and MRI signal intensity of compacted platelets and RBC suspensions of varying haematocrit (Ht), as well as that of model clots and ex vivo pulmonary emboli, where the presence of platelet layers was verified by immunohistochemistry. Our expectation was that MRI would allow discrimination among platelet layers and RBC-rich areas in thrombi due to redistribution of extracellular serum in the platelet-rich part and the RBC-rich part of the clot.

---

## Materials and methods

Pulmonary emboli were collected within 24 h after death during routine post-mortem examinations of patients who died of massive pulmonary embolism. Our study did not interfere with the course of autopsy and the Committee of the Republic of Slovenia for Medical Ethics approved the protocol. The emboli were rinsed with phosphate-buffered saline, pH 7.4, containing 0.2% sodium azide and were subjected to examination by MRI and subsequently to immunohistochemical staining of platelets (anti  $\beta$ -3 integrin Anti Human CD 61, Dako Cytomation, Denmark) and RBC (Anti Human Glycophorin A, Dako Cytomation, Denmark) as described before (Tratar et al. 2007).

In order to prepare sedimented platelets as a model for platelet aggregates, recently expired platelet concentrate (obtained from the Centre for Transfusion Medicine of the Republic of Slovenia) was aliquotted from a standard 450-ml bag into plastic vials and centrifuged (Tehtnica,

Slovenia) for 15 min at 3,000 rpm. The plasma supernatant was removed by pipette and the sedimented platelets because of their viscosity and was transferred manually using a glass spoon-like rod into Teflon containers. These vials were placed for a second round of centrifugation into a swing-out bucket microcentrifuge (Jouan Refrigerated Bench Top Centrifuge, MR22, USA) for 5 min at 3,000 rpm. In order to remove redundant extracellular fluid, the remaining drops were abstracted by an insulin syringe (insulin syringe with BD Microlance Kanuele 26G 0.45 mm × 16 mm, TIK, Slovenia). To prepare pure platelet clots, platelet concentrate was centrifuged once for 15 min at 3,000 rpm, the supernatant was removed and about 1 ml of sedimented platelets was mixed with 50 µl of thrombin (Thrombin, Sigma Germany) at 20 NIH unit/ml and 50 µl of CaCl<sub>2</sub> at 2 mol/l. The platelet clot was allowed to retract spontaneously. As the expressed fluid could spoil clot relaxation time measurements, it was abstracted by an insulin syringe (insulin syringe with BD Microlance Kanuele 26G 0.45 mm × 16 mm, TIK, Slovenia) before NMR relaxometry and MRI.

Red blood cells suspensions, as a model for clots with a defined RBC content, were prepared from whole blood, collected from the cubital vein of healthy volunteers into vials (Vacutainer, Becton-Dickinson, Germany) containing one volume part of 0.129 mol/l Na-citrate for nine volume parts of blood. RBC were compacted by twofold centrifugation (15 min at 3,000 rpm in a Mikro 22R microcentrifuge, Hettich, Canada). The haemoglobin concentration of the volunteers' blood was 125–145 g/l, the haematocrit (Ht) 35–42% and the plasma fibrinogen concentration 1.2–1.8 g/l. The plasma supernatant was removed after each centrifugation and replaced by citrated plasma of a matching ABO blood group. No thrombin was added.

Suspensions with a defined Ht (ranging from pure plasma with Ht = 0 to a packed RBC sample with Ht = 100%) were then prepared in Teflon vials with a diameter of 5 mm and a height of 30 mm by mixing RBC and plasma. Preparation and manipulation of samples was performed in a nitrogen atmosphere using a glove bag (model S-20-20, I2R Instruments for Research and Industry, USA) in order to prevent haemoglobin from oxidizing. Blood gas analysis of venous blood upon sampling revealed an oxyhaemoglobin saturation of 0.45, corresponding to 45% of diamagnetic oxyhaemoglobin and 55% of paramagnetic deoxyhaemoglobin.

Model whole blood clots were prepared from venous blood of the same donors, collected without an anticoagulant. Clotting was induced in vitro in Teflon vials by adding thrombin (Thrombin, Sigma, Germany) in a final concentration of 1 NIH unit/ml. Clots were either allowed to spontaneously retract to about 3/4 of their original volume after they had been gently detached from the tube walls with a needle, or retraction was pharmacologically inhibited by adding the phosphodiesterase inhibitor UDCG 212 (Boehringer, Germany) in a final concentration of 20 µmol/l (Tratar et al. 2004). The effect of retraction on clot Ht was estimated by multiplying the initial Ht by the ratio between the initial clot mass and the clot mass after 3 h

of retraction.

All samples were examined by 3-dimensional high-resolution MRI in a 2.35 T (100 MHz proton frequency) horizontal bore Oxford superconducting magnet (Oxford Instruments, Oxon, UK), equipped with a Bruker micro-imaging gradient system (Bruker, Ettlingen, Germany) using TecMag NMR spectrometer and computer software (TecMag, Huston TX, USA).  $T_1$ -weighted MRI was performed using the conventional 3D spin-echo MRI method with the following parameters: TE and TR were TE/TR = 10/120 ms, imaging field of view was 41 mm in all three spatial directions and the imaging matrix was 256 (axial direction) by 128 by 128 (radial directions). No signal averaging was used so that the total imaging time was 33 min.

The proton relaxation times of regions of interest in MR images of pulmonary emboli, model clots and cell samples were reconstructed from 8-bit MR images, where the darkest pixels were assigned the signal intensity  $I = 0$  and the brightest  $I = 255$ , according to the expression:

$$I \propto \rho(1 - \exp(-TR/T_1)) \exp(-TE/T_2), \quad (1)$$

where  $\rho$  is the proton density and TR and TE are the repetition time and echo time, respectively.

To obtain  $T_1$ , TE was held constant at 10 ms and TR was varied from 200 to 3,200 ms.

Estimation of  $T_2$  was done at a constant TR of 1,000 ms and TE was varied from 10 to 160 ms.

The  $T_1$  and  $T_2$  values were fitted according to (Eq. 1).

For assessing the signal intensity ratio between RBC ( $I_{RBC}$ ) and platelets ( $I_P$ ), the ratio of the corresponding proton densities  $\rho_{RBC}/\rho_P$  was estimated from model clots containing platelet areas that were imaged by the 3D spin-echo method at parameters TR/TE = 2,500/2.37 ms. The estimated proton density  $\rho_{RBC}/\rho_P$  was equal to 0.91 indicating that the water content in both tissues was almost identical. For image analysis, we used the MRI Analysis Calculator of the ImageJ program (NIH, USA).

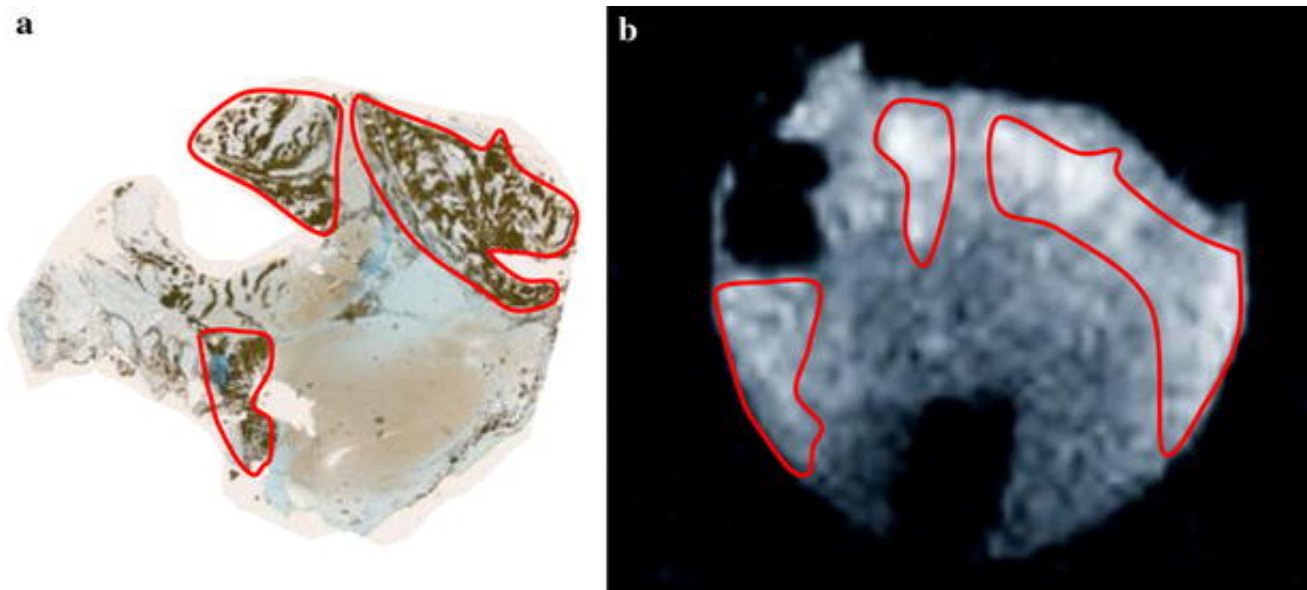
$T_1$  and  $T_2$  relaxation times of RBC suspensions with a varying haematocrit and those of pure, sedimented platelets were measured separately.  $T_1$  relaxation time measurements were made at room temperature (22°C) by the inversion recovery spectroscopic pulse sequence technique.  $T_2$  relaxation time measurements of the same samples were made by the Carr–Purcell–Meiboom–Gill method (Meiboom and Gill 1958).

Differences between any two compared sets of variables were tested for statistical significance by the two-tailed Student's  $t$ -test and were considered significant at  $P < 0.05$ .

---

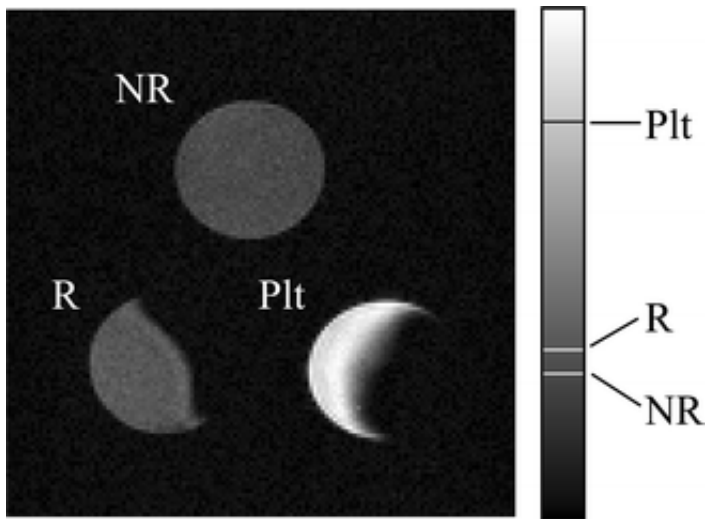
## Results

Semiquantitative assessment of bright areas in  $T_1$ -weighted MRI of pulmonary emboli ex vivo and immunohistochemical staining for platelets (Fig. 1) confirmed that  $T_1$ -weighted MRI discriminates between brighter, platelet-rich areas and darker, RBC-rich areas, as has been recently described (Tratar et al. 2007). Comparable differences in signal intensity were measured also in  $T_1$ -weighted MR images of pure platelet clots in comparison to whole blood clots (Fig. 2). The model platelet clot (Plt) on average yielded three-times brighter signal in  $T_1$ -weighted MRI than a non-retracted whole blood clot (NR), prepared from venous blood with an Ht of 0.35 and a oxyhaemoglobin content of 45%. The difference in signal intensities ( $252 \pm 5$  versus  $105 \pm 5$ ) was highly significant by Student's  $t$ -test ( $P < 0.001$ ). A very similar result was obtained with pure, sedimented platelets in comparison to an RBC suspension with a haematocrit of 0.40, indicating that the fibrin network, comprising less than 1% of the total clot mass in model clots, did not significantly affect the water proton relaxation properties. The retracted clot (R) yielded a brighter MR signal in  $T_1$ -weighted MRI than the non-retracted clot (NR). The signal was inversely proportional to the estimated haematocrit level and was 2.6 times lower than the signal from the model platelet clot (Plt) for a retracted clot with Ht = 58% (R). According to our model, based on the relaxation time properties of various Ht levels, the  $I_{RBC} / I_P$  ratio in the retracted clot (R) corresponded to Ht of 0.52. Ht levels assessed by  $I_{RBC} / I_P$  ratios in the retracted clot (R) deviated from Ht levels assessed by clot mass ratios by no more than 8%.



**Fig. 1**

Pulmonary embolus ex vivo in a transverse cross-section. Comparison of immunohistochemical staining of platelets (a) and bright regions in  $T_1$ -weighted MRI (b). In  $T_1$ -weighted MRI, platelet-rich areas displayed a distinctively brighter signal than the red cell areas of the embolus. The regions of interest are roughly outlined (red line) for easier comparison. Original magnification  $\times 10$



**Fig. 2**

$T_1$ -weighted spin-echo MRI ( $TR/TE = 120/10$  ms) of a non-retracted whole blood clot with Ht = 40% (NR), a retracted whole blood clot (R) where Ht increased from 42 to 58% and of a pure platelet clot (Plt). The pure platelet clot appeared three times brighter than the non-retracted whole blood clot, while the retracted clot appeared brighter than the non-retracted clot but still 2.6 times less intensive than the pure platelet clot

In order to investigate how RBC density in samples affects the proton relaxation times  $T_1$  and  $T_2$ , which in turn determine the MRI signal intensity, we measured the relaxation times of RBC suspensions of varying haematocrit, obtained from venous blood, in comparison to pure, sedimented platelets (Table 1). We neglected the effects of fibrin polymerization on the magnetic relaxation of protons in model clots, because the content of fibrin in non-retracted or non-compacted model clots is very small and has a very limited effect on  $T_1$  and  $T_2$  (Blinic et al. 1990). Our results showed that at 40–60% haematocrit the  $T_1$  of an RBC suspension could be clearly distinguished from that of sedimented platelets (with a statistically significant difference  $P < 0.05$ ), while at higher haematocrit (80–100%), discrimination was no longer possible, as the differences were not statistically significant ( $P > 0.05$ ).

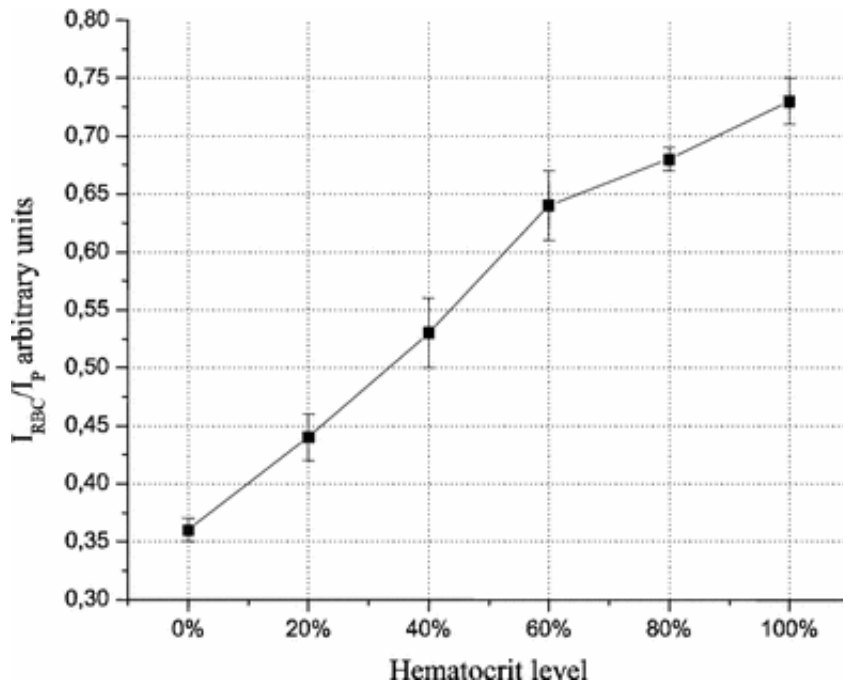
**Table 1**

Measured  $T_1$  and  $T_2$  relaxation times in RBC samples of various Ht levels and sedimented pure platelets

Sample content	$T_1$ (ms)	$T_2$ (ms)
Plasma	1991 ± 59	403 ± 20
RBC 20% Ht	1612 ± 64	262 ± 25
RBC 40% Ht	1277 ± 66	145 ± 13
RBC 60% Ht	1029 ± 55	112 ± 10
RBC 80% Ht	950 ± 23	94 ± 6
RBC 100% Ht	869 ± 18	84 ± 1
Platelet clot	874 ± 310	91 ± 10


Using the measured  $T_1$  and  $T_2$  values from Table 1 and the imaging parameters  $TR/TE = 120/10$  ms, we calculated the expected MRI intensity ratio between RBC-rich clots of varying haematocrit and that of pure platelet clots, i.e. the  $I_{RBC}/I_P$  ratio, using Eq. 1. The results of  $I_{RBC}/I_P$  as a function of haematocrit are shown in Fig. 3. The calculated ratio of a non-retracted whole blood clot (at 40% haematocrit and imaging parameters  $TR/TE = 120/10$  ms) in comparison to a pure platelet clot was 0.56 and the measured  $I_{RBC}/I_P$  ratio from Fig. 2 was 0.54, which is a very good agreement. Interestingly, the comparison of dark and bright regions from an ex vivo pulmonary embolus (Fig. 4) yielded a similar  $I_{RBC}/I_P$  ratio of 0.51, indicating that the RBC-rich part of the embolus retained a relatively abundant extracellular space, although it would be expected to have undergone retraction and some degree of mechanical compaction.





**Fig. 3**

Graph of the signal intensity ratios  $I_{RBC}/I_P$  between RBC-rich clots with varying haematocrit in comparison to pure platelet clots, as a function of haematocrit. The signal intensity ratios are calculated from the measured relaxation times in Table 1 and imaging parameters  $TR/TE = 120/10$  ms, using (Eq. 1). Means  $\pm$  SD are shown



**Fig. 4**

Pulmonary embolus ex vivo in a  $T_1$ -weighted MRI ( $TR/TE = 120/10$  ms) showing distinctive bright platelet layers (*white arrows*) and dark red cell-rich areas (*encircled*). The image intensity ratio between the bright layers and darker region, i.e. the  $I_{RBC}/I_P$  ratio, was 0.51

## Discussion and conclusion

The aim of our research was to find a biophysical explanation why discrimination between RBC-rich parts and platelet layers of blood clots is possible by  $T_1$ -weighted MRI, as has been recently described by our group in pulmonary emboli (Tratar et al. 2007) and another group in

experimental clots (Viereck et al. 2005). Since platelet-rich regions are quite resistant to thrombolysis (Weisel 2007), the ability of MRI to depict platelet-rich regions in blood clots might be of interest in non-invasive prediction of clot lysability.

Knowing that water diffuses into the intra- and extracellular regions of blood cells in times comparable to or shorter than the relaxation times of water protons in cells (Gupta 1987), we performed experiments with changing RBC haematocrit levels to mimic different levels of clot retraction in order to find out at what RBC density the red part of the clot reaches the signal intensity of aggregated platelets. Our results showed significantly longer  $T_1$  values and correspondingly lower MRI signal intensities in  $T_1$ -weighted images for RBC samples with a haematocrit of up to 60% in comparison with pure platelets, whereas discrimination was no longer possible at an RBC haematocrit of 80–100%. Thus, although RBC contained paramagnetic deoxyhaemoglobin (in a ratio of 0.55/0.45 with diamagnetic oxyhaemoglobin), the overall proton spin-lattice relaxation of samples containing ample extracellular fluid was less effective than the proton spin-lattice relaxation of compacted platelets, containing only diamagnetic proteins. The most plausible explanation for these results is that tight platelet aggregation, simulated by sedimentation in our in vitro experiments, eliminates essentially all extracellular fluid from platelet aggregates and effectively concentrates cellular proteins, thus facilitating proton spin-lattice relaxation even in the absence of paramagnetic centres. The effect of shorter spin lattice relaxation times in platelet aggregates versus red cell-rich parts of the clot may be further augmented by the change in platelet shape from discoid to flattened with numerous pseudopodia (Ruggeri 1997; Savage et al. 2001), thus increasing its surface-to volume ratio and magnetic susceptibility.

There was no measurable difference in  $T_1$ -weighted MR signal intensity between compacted platelets prepared with or without clotting, i.e. fibrinogen polymerization, nor was there any significant difference between the  $T_1$ -weighted MR signal intensity of an RBC suspension in plasma at 40% haematocrit and non-retracted clots from whole blood (with Ht of 35–42%), which implies that the cell density is the most important parameter determining MR image intensity, and that the small quantity of fibrin in model clots does not play an important role. This is in accordance with earlier studies (Blackmore et al. 1990; Blinc et al. 1990, 1992). We only compared RBC samples to pure, compacted platelets—and not various mixtures of platelets with RBC—because activated platelets in vivo tightly bind to each other during platelet aggregation and form distinct platelet layers within the clot (Ruggeri 1997; Savage et al. 2001).

The  $T_1$ -weighted MRI parameters (TR/TE = 120/10 ms) were chosen to mimic those of our earlier study (Tratar et al. 2007). We found these parameters to be the best compromise between image contrast and image quality. A shorter repetition time would introduce heavier  $T_1$

weighting but also more image noise, whereas a longer repetition time would result in less image contrast but better signal-to-noise ratio and also prolong the scanning time.

A limitation of our experimental work is associated with the reliability of the  $T_1$  relaxation time of sedimented platelets due to the complex platelet nature, which makes sample manipulation difficult. Platelet manipulation (i.e. extraction, multiple centrifugations) might have caused their membrane disruption, but that had little effect on the proton relaxation properties in view of the scant extracellular space. As for the red cell suspensions, the proton relaxation time measurements are valid for venous blood with a ratio of paramagnetic deoxyhaemoglobin to diamagnetic oxyhaemoglobin of 55/45. If the deoxygenation of haemoglobin proceeded further, as might be expected in severe hypoxia, the proton relaxation times in clots from fully deoxygenated blood would be expected to shorten and blur the distinction from platelet layers.

In conclusion, tightly packed platelets display a brighter signal in  $T_1$ -weighted MRI than red cell-rich areas of clots from venous blood with a Ht up to 60%. At higher Ht (80–100%), which could be associated with mechanical clot compaction, MRI discrimination would no longer be possible.

## Acknowledgments

We thank Dr Dragoslav Domanovič from the Blood Transfusion Centre of the Republic of Slovenia for providing human plasma and platelet concentrate.

---

## References

Blackmore CC, Francis CW, Bryant RG, Brenner B, Marder VJ (1990) Magnetic resonance imaging of blood and clots in vitro. *Invest Radiol* 25:1316–1324

[CrossRef](#) 

Blinc A, Lahajnar G, Blinc R, Zidansek A, Sepe A (1990) Proton NMR study of the state of water in fibrin gels, plasma, and blood clots. *Magn Reson Med* 14:105–122

[CrossRef](#) 

Blinc A, Keber D, Lahajnar G, Zupancic I, Zorec-Karlovsek M, Demsar F (1992) Magnetic resonance imaging of retracted and nonretracted blood clots during fibrinolysis in vitro.

*Haemostasis* 22:195–201

Francis CW, Totterman S (1995) Magnetic resonance imaging of deep vein thrombi correlates with response to thrombolytic therapy. *Thromb Haemost* 73:386–391

Gupta RK (1987) *NMR spectroscopy of cells and organisms*. CRC Press, Boca Raton

Kozak M, Mikac U, Blinc A, Sersa I (2005) Lysability of arterial thrombi assessed by magnetic resonance imaging. *Vasa* 34:262–265

CrossRef [↗](#)

Meiboom S, Gill D (1958) Modified spin-echo method for measuring nuclear relaxation times. *Rev Sci Instrum* 29:688–691

CrossRef [↗](#) ADS [↗](#)

Ruggeri ZM (1997) Mechanisms initiating platelet thrombus formation. *Thromb Haemost* 78:611–616

Savage B, Cattaneo M, Ruggeri ZM (2001) Mechanisms of platelet aggregation. *Curr Opin Hematol* 8:270–276

CrossRef [↗](#)

Stump DC, Mann KG (1988) Mechanisms of thrombus formation and lysis. *Ann Emerg Med* 17:1138–1147

CrossRef [↗](#)

Tratar G, Blinc A, Strukelj M, Mikac U, Sersa I (2004) Turbulent axially directed flow of plasma containing rt-PA promotes thrombolysis of non-occlusive whole blood clots in vitro. *Thromb Haemost* 91:487–496

Tratar G, Blinc A, Podbregar M, Kralj E, Balazic J, Sabovic M, Sersa I (2007) Characterization of pulmonary emboli ex vivo by magnetic resonance imaging and ultrasound. *Thromb Res* 120:763–771

CrossRef [↗](#)

Viereck J, Ruberg FL, Qiao Y, Perez AS, Detwiller K, Johnstone M, Hamilton JA (2005) MRI of atherothrombosis associated with plaque rupture. *Arterioscler Thromb Vasc Biol* 25:240–245

Weisel JW (2007) Structure of fibrin: impact on clot stability. *J Thromb Haemost* 5(Suppl 1):116–124

CrossRef [↗](#)

---

Over 8.5 million scientific documents at your fingertips  
© Springer International Publishing AG, Part of Springer Science+Business Media

[springeropen.com](http://springeropen.com)

High quality  
thanks to  
rigorous peer  
review



 Springer Open