

# Safety of gadolinium contrast angiography in patients with chronic renal insufficiency

Albert D. Sam II, MD,<sup>a</sup> Mark D. Morasch, MD,<sup>a</sup> Jeremy Collins, MD,<sup>b</sup> Gina Song, MD,<sup>b</sup> Richard Chen, MD,<sup>b</sup> and F. Scott Pereles, MD,<sup>b</sup> *Chicago, Ill*

**Objective:** To prevent iodinated contrast medium–induced nephrotoxicity, gadolinium has been used increasingly for magnetic resonance angiography (MRA) or conventional digital subtraction angiography (DSA) to visualize arterial anatomy in patients undergoing vascular surgery who are considered at high risk because of chronic renal insufficiency. We assessed the safety of gadolinium-based contrast medium as a substitute for iodinated contrast medium–enhanced examinations. We determined the incidence of gadolinium-induced nephrotoxicity in a clinical setting and searched for contributing risk factors.

**Patients and Methods:** In a single-center retrospective study from December 1999 to January 2001, 218 inpatients underwent MRA and 42 inpatients underwent DSA, with gadolinium as the sole contrast agent. Patient comorbid conditions, indications for vascular imaging, contrast dose, urine output, baseline and post-procedure serum creatinine concentration (SCr), and outcome were recorded for all patients in whom gadolinium-induced renal failure developed.

**Results:** Of 260 patients who received gadolinium-based contrast agents, at a dose of 0.25 mmol/kg or more, 195 patients (75%) had pre-test baseline chronic renal insufficiency. In 7 of 195 patients (3.5%) acute renal failure developed after gadolinium-based contrast medium administration, for MRA (n = 153) in 3 patients (1.9%) and DSA (n = 42) in 4 patients (9.5%). Average baseline SCr in the 195 patients with chronic renal insufficiency was  $38.2 \pm 1.6$  mL/min/1.73 m<sup>2</sup>, and in the 7 patients in whom acute renal failure developed, baseline SCr was  $32.5 \pm 7.8$  mL/min/1.73 m<sup>2</sup> (P = .33). Respective intravenous and intra-arterial gadolinium doses in these 7 patients ranged from 0.31 to 0.41 mmol/kg for MRA and 0.27 to 0.42 mmol/kg for DSA. Acute renal failure did not develop in any of 65 patients with normal baseline SCr.

**Conclusion:** Despite reports of negligible nephrotoxicity, rarely gadolinium-based contrast agents can cause acute renal failure in patients with underlying chronic renal insufficiency. Estimation of creatinine clearance alone does not enable prediction of which patients are likely to have acute renal failure. Patients at high-risk should be identified, and prophylactic measures should be taken to reduce the risk for nephrotoxicity. (*J Vasc Surg* 2003;38:313-8.)

Specific comorbid conditions such as chronic renal insufficiency are important to consider when contemplating angiography to evaluate vascular lesions. Iodinated contrast agents used during radiographic evaluation of the vascular tree are nephrotoxic, and not uncommonly they can induce renal failure. Gadolinium-based contrast formulations are noniodinated contrast agents that are predominately infused intravenously during vascular imaging with magnetic resonance angiography (MRA). Intravenous gadolinium-based contrast medium is safe and well-tolerated, with no nephrotoxicity when given within recommended dosages.<sup>1-3</sup> Prospective studies have evaluated the safety of gadolinium, but have been criticized because of relatively small sample sizes.<sup>4</sup> Patients in several of these studies received a much lower dose of gadolinium (0.1 mmol/kg) than is commonly infused during routine clinical MRA. Gadolinium is also used as an intra-arterial alternative to

iodinated contrast agents during catheter-based digital subtraction angiography (DSA). This off-label usage is generally considered safe despite a paucity of strong evidence.

Two recent reports of renal failure after intra-arterial infusion of gadolinium have led to new questions regarding its clinical safety.<sup>5,6</sup> We undertook this investigation in an attempt to identify the incidence of gadolinium-induced nephropathy, and we sought to identify risk factors that may predispose to this complication.

## METHODS

Records for all 260 inpatients who received high-dose intravenous or intra-arterial gadolinium (0.25 mmol/kg or greater) at Northwestern Memorial Hospital from December 1999 to January 2001 were reviewed retrospectively according to guidelines indicated by the Northwestern University Medical School Institutional Review Board. The average age of the study population was 62 years (range, 20-92 years). During that 24-month period 218 inpatient gadolinium-enhanced peripheral MRA examinations (non-cardiac thoracic, mesentero-renal, and lower extremity) were performed. During that same time period 42 inpatients underwent DSA in the interventional radiology suite or in the operating room, with gadolinium as the sole intra-arterial contrast agent. Charts for all 260 inpatients were reviewed, and baseline renal function was calculated.

From Northwestern Memorial Hospital, The Feinberg Northwestern University Medical School, Departments of Surgery, <sup>a</sup>Division of Vascular Surgery, and <sup>b</sup>Department of Radiology.

Competition of interest: none.

Reprint requests: Mark D. Morasch, MD, Division of Vascular Surgery, Ste 10-105, 201 E Huron St, Chicago, IL 60611. (e-mail: mmorasch@nmh.org).

Copyright © 2003 by The Society for Vascular Surgery and The American Association for Vascular Surgery.

0741-5214/2003/\$30.00 + 0

doi:10.1016/S0741-5214(03)00315-X

**Table 1.** Characteristic of patients with gadolinium-induced nephrotoxicity

Patient	Age (y)	Sex	HTN	Diabetes	Test	Indication	Gadolinium dose		Creatinine clearance (mL/min/1.73 m <sup>2</sup> )	Dialysis required
							mL	mmol/kg		
1	52	M	No	No	DSA-Aorta	Renal failure	60	0.42	29	Yes
2	53	M	Yes	Yes	DSA-LE	Ischemia	110	0.39	61	No
3	82	F	Yes	Yes	MRA	Groin mass	40	0.39	9	No
4	70	M	No	No	MRA	LE ischemia	60	0.41	17	Yes
5	86	M	Yes	No	DSA-Aorta	Iliac pseudoaneurysm	40	0.27	15	Yes
6	92	M	Yes	Yes	DSA-LE	LE ischemia	60	0.34	41	No
7	66	M	Yes	Yes	MRA	LE ischemia	60	0.31	56	No

HTN, Hypertension; DSA, digital subtraction angiography; MRA, magnetic resonance angiography; LE, lower extremity.

Patients who had acute renal failure within 48 hours of administration of the agent were identified and their charts reviewed in further detail. Patient history, hospital admission status, concomitant medications, comorbid conditions, indication for vascular imaging, urine output, and baseline pre-test and daily inpatient laboratory values were recorded from the medical records of patients in whom renal failure developed. Chronic renal insufficiency was defined as creatinine clearance less than 80 mL/min/1.73 m<sup>2</sup>. Serum creatinine concentration (SCr) was recorded as milligrams per deciliter, and creatinine clearance was calculated according to the formula  $(140 - \text{age} \div 72 \times \text{SCr}) \times \text{weight}$  in kilograms (multiplied by 0.85 for female patients). Acute renal failure was defined as an increase in SCr greater than 1.0 mg/dL within 48 hours of gadolinium infusion<sup>7</sup> and concomitant oliguria (urine output <0.1-0.5 mL/kg/h) or anuria (urine output <0.1 mL/kg/h).

## RESULTS

Of 260 patients, 195 (75%) had chronic renal insufficiency, defined as baseline creatinine clearance less than 80 mL/min/1.73 m<sup>2</sup>. Of 218 patients who underwent MRA, 153 patients (70%) had baseline chronic renal insufficiency (average pre-test SCr, 2.1 mg/dL; average creatinine clearance, 60.8 mg/mL/1.73 m<sup>2</sup>), whereas all 42 patients (100%) who underwent gadolinium-enhanced DSA had baseline chronic renal insufficiency (average pre-test SCr, 2.6 mg/dL; average creatinine clearance, 39.6 mg/mL/1.73 m<sup>2</sup>). In 7 of 195 patients with chronic renal insufficiency, gadolinium-induced acute renal failure developed after either MRA or DSA, for a combined incidence of 3.5%. In 3 patients (1.9%) renal failure developed after intravenous infusion of gadolinium during MRA, and in 4 patients (9.5%) similar anuric complications developed after gadolinium-enhanced DSA. None of 65 patients with normal creatinine clearance of greater than 80 mg/mL/1.73 m<sup>2</sup> had renal failure after gadolinium administration.

No other complications were related to performance of the examinations in these patients. Average age of the 195 patients with baseline chronic renal insufficiency was 61 years (range, 20-92 years), whereas average age of patients in whom acute renal failure developed was 71.5 years (range, 52-92 years). Six patients with acute renal failure

were men, and one was a woman. None of the patients who developed renal failure had a history of allergy to iodine-based contrast agents or received other forms of contrast material within 10 days before gadolinium infusion. No patient with acute renal failure had begun angiotensin converting enzyme (ACE) inhibition therapy within 30 days, or exhibited signs or symptoms of systemic infection, clinical instability, or deviation from baseline renal function before the period of observation. No patient had received an organ transplant.

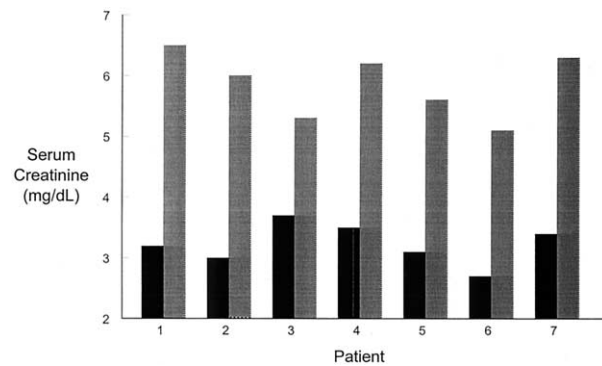
In the 7 patients with renal failure, average pre-test SCr was 2.5 mg/dL, and baseline creatinine clearance before receiving gadolinium was 32.5 mL/min/1.73 m<sup>2</sup> (range, 9-61 mL/min/1.73 m<sup>2</sup>). This compares with average baseline SCr of 2.2 mg/dL ( $P = .27$ ) and average baseline creatinine clearance of  $38.2 \pm 1.6$  mL/min/1.73 m<sup>2</sup> ( $P = .33$ ) in the 195 patients determined to have baseline pre-test chronic renal insufficiency. Urinalysis in 7 patients with oliguria showed granular cast formations in 4 patients and low-grade proteinuria in 3 patients. Other risk factors noted in the 7 patients with acute renal failure included hypertension (71%), diabetes (57%), and known renal artery stenosis (29%) (Table). Five of 7 patients (71%) were receiving long-term ACE inhibitor therapy; all stopped at least 3 days before the examination).

Gadolinium-enhanced studies that resulted in acute post-examination renal failure included DSA of the aorta ( $n = 2$ ), DSA of lower extremity vasculature ( $n = 2$ ), and MRA to display the infrarenal aorta and lower extremity vessels ( $n = 3$ ). Indications for aortic DSA were diagnosis and endovascular treatment of renal artery stenosis in 1 patient and evaluation of an iliac pseudoaneurysm in 1 patient. One MRA study was performed to evaluate a pulsatile groin mass. The remaining DSA and MRA studies were performed to evaluate lower extremity ischemia (Table). All patients received undiluted triple-dose gadopentetate dimeglumine (dihydrogen[*N,N*-bis[2-bis(carboxymethyl)amino]ethyl]-glycinate(5-)] gadolinate (2-). Average gadolinium dose administered in the 195 patients was 45 mL (0.28 mmol/kg). In 5 of 7 patients with acute renal failure the total dose did not exceed 0.4 mmol/kg. Two patients received total doses of 0.41 and 0.42 mmol/kg, respectively. The highest gadolinium dose was administered dur-

ing DSA and renal artery stenting procedure to treat renal artery stenosis and ischemic nephropathy. SCr in all 7 patients were noted on each inpatient day, and is presented as an average value (Fig 1). Each patient's baseline pre-MRA SCr served as a control value. Four patients had oliguria and 3 patients had anuria during the observation period (Fig 2). SCr peaked 3 days (range, 2-5 days) after gadolinium infusion, and returned to baseline on day 7 (range, 4-12 days). Three patients temporarily required inpatient hemodialysis. In these 3 patients SCr peaked at 4 days (range, 4-5 days) and baseline renal function was regained after 10 days (range, 9-12 days). In the 4 patients who did not receive dialysis SCr peaked after 3 days (range, 2-4 days), and values returned to baseline on day 6 (range, 4-8 days). Three patients (43%) subsequently underwent arterial reconstruction surgery during the index admission; the remaining patients were discharged as soon as renal function recovered. Average hospital stay was 13.2 days (range, 7-27 days). One patient died in the hospital, of exacerbated congestive heart failure. Two patients, one who required acute temporary dialysis and one who did not, ultimately required long-term hemodialysis because of deterioration in renal function.

## DISCUSSION

Renal insufficiency combined with comorbid conditions in patients with peripheral vascular disease increases the incidence of contrast-induced renal failure after angiography. In a study by Berns,<sup>8</sup> 3.6% of patients with baseline pre-procedure SCr less than 2.0 mg/dL had iodinated contrast-induced nephrotoxicity. This incidence increases to 47% when SCr is 2.0 to 4.0 mg/dL, and climbs to more than 80% with SCr greater than 4.0 mg/dL.<sup>8</sup> Iodinated contrast-induced renal failure may require temporary dialysis in as many as 25% of affected patients. This increases the length of stay, cost, and complexity of a given hospitalization, and increases inpatient mortality.<sup>9</sup> Three mechanisms are purported to cause contrast-induced nephrotoxicity from iodinated contrast media. Macrocirculatory and microcirculatory vasoconstriction occurs in response to radiocontrast dye. In addition, direct tubular toxicity and precipitation of dye crystals within the renal tubules occur. Prophylactic measures to prevent contrast-induced nephropathy include pre-test intravenous hydration, acetylcystine administration, and, most recently, dopamine receptor stimulation. In patients at high-risk, periprocedural hydration to maintain urine output greater than 150 mL/hr resulted in a near 25% reduction in rate of contrast-induced nephropathy in one review.<sup>10</sup> Acetylcystine, a thiol-containing compound, administered at a dose of 600 mg twice daily for 2 days before the procedure, on the day of the procedure, and 1 day post-procedure likely guards against contrast-induced nephropathy, because of its antioxidant effects.<sup>11</sup> Although in current use, larger confirmatory clinical trials are warranted. The latest strategy to prevent contrast-induced nephropathy involves maintaining glomerular filtration via selective activation of renal dopamine A<sub>1</sub> receptors. Dopamine A<sub>1</sub> agonism results in



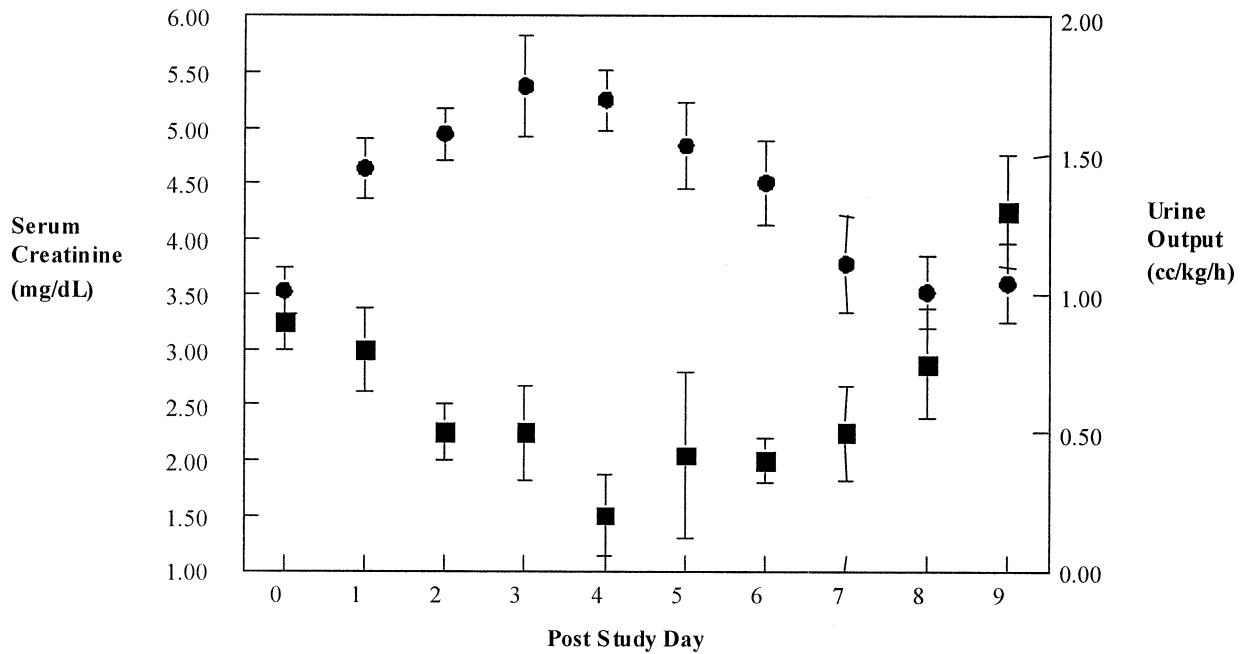
**Fig 1.** Baseline (*black columns*) and peak serum creatinine concentration (*gray columns*) in 7 patients with gadolinium-induced nephrotoxicity.

increased renal blood flow, primarily in the inner renal cortex and medulla, which are the areas most susceptible to contrast-induced toxicity.<sup>12</sup> Randomized trials using this new prophylactic agent are ongoing.

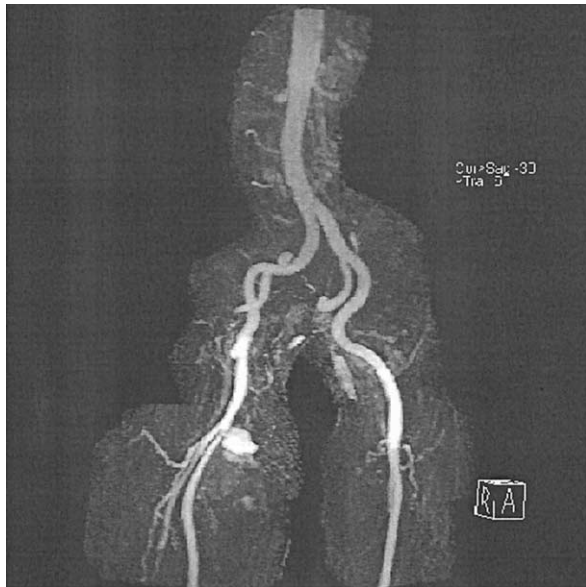
Gadolinium-based preparations have been developed for use as substitutes for iodinated contrast medium. One perceived advantage is that gadolinium-based contrast agents are thought to have negligible nephrotoxicity. These agents are most commonly used intravenously to reduce proton relaxation time and improve image quality at MRA. They have also been injected intra-arterially as a substitute for iodinated contrast medium during DSA. We describe 7 patients, all with preinfusion renal insufficiency, in whom acute oliguric and anuric renal failure developed after gadolinium infusion.

Gadolinium is a paramagnetic metallic element most often used in contrast medium preparations for magnetic resonance imaging (MRI). The contrast-enhancing effect of the agent used in this series is brought about by the di-*N*-methylglucamine salt of gadopentetate, the gadolinium complex of diethylene-triamine-pentaacetic acid (Gd-DTPA). During T<sub>1</sub>-weighted imaging, gadolinium shortens the spin-lattice relaxation time of the excited nuclei, resulting in enhanced signal intensity on MRI.<sup>13</sup> The addition of gadolinium-based contrast agents reduces MRA time dramatically and can improve image quality compared with older non-contrast-enhanced time-of-flight techniques (Figs 3 and 4).

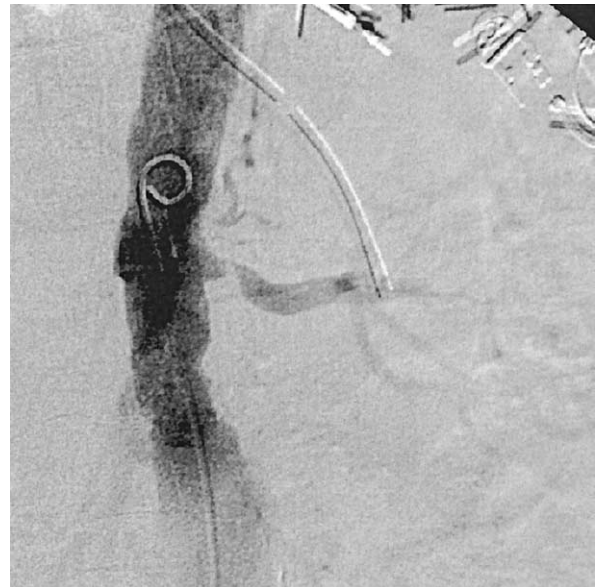Similar to other radiocontrast agents, gadolinium may result in nephrotoxicity as a result of the combined effects of direct cellular toxicity and by increasing the concentration of urine. The normal medullary system is hypoxic (10-20 mm Hg) and thus is susceptible to injury when further hypoxic-inducing insults are present. The cellular oxidant stress conditions resulting from contrast filtration induce cellular ischemia and result in injury to the outer medullary thick ascending limb of the renal tubule. Gadolinium is thought to have much less toxic renal tubular effects compared with iodinated agents, despite their similar behavior and excretory profiles. The pharmacokinetics



**Fig 2.** Serum creatinine concentration (*circles*) and urine output (*squares*) throughout observation period in 7 patients. Data represent mean  $\pm$  SEM.



**Fig 3.** Magnetic resonance angiogram with gadolinium contrast enhancement shows pseudoaneurysm of the right profunda femoris artery.



**Fig 4.** Digital subtraction angiogram with gadolinium contrast enhancement shows a stenotic renal artery.

of the gadolinium preparation used in our series, gadopentetate dimeglumine, is similar to that of iodinated contrast agents. After administration, the compound is distributed rapidly in the extracellular space, and is eliminated, unchanged, by glomerular filtration in a dose-independent fashion. Gadolinium ions form a stable complex with

DTPA that is intensely hydrophilic. Gadopentetate behaves like biologically inert compounds such as mannitol or inulin, with no noteworthy protein binding or inhibitory interaction with enzymes. For doses up to 0.25 mmol of gadopentetate per kilogram the plasma half-life is 90 minutes, corresponding to renal filtration rate. Renal clearance is approximately 120 mL/min/1.73 m<sup>2</sup> and is comparable

to that for substances that are completely filtered, such as inulin or chromium 51–ethylenediamine tetraacetic acid ( $^{51}\text{Cr-EDTA}$ ).<sup>14</sup> At 0.1 mmol/kg there is complete elimination via the kidneys, even in the presence of impaired renal function (creatinine clearance,  $>20$  mL/min).<sup>14</sup> The plasma half-life has been reported to increase in relation to degree of renal insufficiency, without an increase in extrarenal elimination. The half-life increases to 30 hours in these patients, yet there is no toxic degeneration of the gadolinium chelate.<sup>15</sup>

Increasingly, MRA is supplanting angiography for preoperative vascular evaluation. MRA is accurate and reliable for visualizing inflow and runoff vessels and for establishment of stenotic grade if disease is present.<sup>16</sup> Gadolinium enhancement has resulted in greater image accuracy and has helped expand the uses of MRA. It is particularly useful in areas of high flow, such as the aortic arch and in renal and visceral vessels, in which turbulence and motion may reduce the accuracy of conventional time-of-flight MRA. Because MRA can be performed on an outpatient basis, it is more cost-effective than contrast-enhanced angiography.<sup>17</sup> Once proper sequences are programmed into the magnetic resonance equipment software, the primary limitation is the experience of the interpreting surgical team. When assessed appropriately, the information derived from MRA is equally, if not more, sensitive as conventional arteriography.<sup>18,19</sup>

Gadolinium can be used during conventional arteriography in patients with renal insufficiency. It has been used instead of diluted iodinated contrast medium in patients with predisposing risk factors for nephropathy because it has a higher K-edge, which permits imaging with a higher range of kilovoltage compared with that typically used for iodine-enhanced imaging.<sup>20</sup> This is particularly advantageous during abdominal aortic imaging in large patients, because the use of gadolinium (versus diluted iodine) circumvents the need to raise the kilovoltage during angiography, which is known to compromise image quality. Intra-arterial gadolinium infusion performs best during selective angiography in small to medium vessels. Aortic evaluation solely with intra-arterial gadolinium is less effective than with full-strength iodinated contrast medium, because of the large volume of gadolinium required and the high flow rate in the aorta. Gadolinium is useful, however, for selectively visualizing specific major aortic branches, such as the celiac, mesenteric, or renal arteries. It is also useful for endovascular procedures in which multiple, repeated selective angiographic views may be required.

Another advantage of gadolinium, in addition to decreased risk for nephropathy, is the low incidence of allergic reactions.<sup>21</sup> One disadvantage, however, is its cost, which is approximately five times that of iodinated agents.

At present only three contrast agents have been approved by the US Food and Drug Administration for intravenous administration during MRI: Gd-DTPA (Magnevist; Berlex Laboratories, Wayne, NJ), Gd-DTPA-BMA (Omniscan; Sanofi-Winthrop, New York, NY), and Gd-HP-DO3A (Prohance; Bracco Diagnostics, Princeton,

NJ). When given at a typical dose of 0.1 mmol/kg for general MRI, these agents demonstrate equivalent lesion enhancement. Several studies have confirmed the safety of intravenous gadolinium during MRA at doses up to 0.3 mmol/kg, even in patients with renal insufficiency. Contrast medium is most commonly administered in doses of 0.2 to 0.3 mmol/kg for most MRA studies. Carotid MRA is typically performed with a dose of 0.1 mmol/kg. Use of intra-arterial gadolinium has not been thoroughly examined to date, either in animals or in human beings, despite prevalent off-label use. Before this report, the two published cases of gadolinium-induced renal failure occurred after arterial infusions during arteriography.<sup>5,6</sup> From this, the recommendation to limit intra-arterial doses to the maximum range of 0.3 to 0.4 mmol/kg was adopted. If intra-arterial gadolinium were considered, we would agree with that recommendation. In this review, anuria requiring hemodialysis developed in 2 patients who received intra-arterial doses of 0.4 mmol/kg or greater. The incidence of renal failure was higher in those receiving intra-arterial gadolinium infusion (9.5% vs 1.9%). Quite possibly this may be the result of a higher concentration of gadolinium in the renal parenchyma, as opposed to that with intravenous infusion. One factor that also must be considered is microembolic showering to the renal circulation as a result of suprarenal aortic injection of contrast medium. Despite this, based on the limited number in this review, our data do not prove that intra-arterial infusion is more problematic than intra-venous administration of gadolinium. To our knowledge, this is the first report to demonstrate renal failure with doses less than 0.4 mmol/kg, regardless of route, with one patient requiring hemodialysis.

The development of contrast-induced nephropathy is related to the number of risk factors present, with the three most important being renal insufficiency, diabetes mellitus, and volume of contrast agent used. Other risk factors include patient dehydration, advanced age, use of concomitant nephrotoxic drugs, multiple myeloma, heart failure, and liver disease. These risk factors were identified from experience with iodinated contrast agents, but they are likely the same for patients who receive gadolinium-based agents. All patients in this series had renal insufficiency, 2 had renal artery stenosis, and 5 of 7 had diabetes.

It is important to identify risk factors for iodinated or gadolinium-based contrast-induced nephropathy to institute prophylactic measures to reduce the incidence of acute renal failure in this high-risk population. We recommend that the dose not exceed 0.3 mmol/kg, when possible, and that 0.4 mmol/kg be considered the absolute limit.

Our study is limited primarily by its retrospective nature and lack of a control group. It is, however, the first to attempt to quantify the incidence of an event reported only twice previously. Since we limited our evaluation to inpatients receiving high doses of gadolinium, it is almost certain that we have overestimated the true overall incidence of gadolinium-induced renal failure because of selection bias. By limiting this study to inpatients, however, we are confident that we did not miss patients who may have

experienced renal toxicity unknowingly. As a corollary, patients with known renal insufficiency who receive gadolinium on an outpatient basis may need to be monitored after discharge.

Acute anuric renal failure can occur after use of gadolinium-based contrast agents in patients with underlying renal insufficiency. Although the incidence is much lower than with iodinated agents, patients at high risk must be identified before infusion, and appropriate prophylactic measures should be taken to reduce the incidence of contrast-induced nephropathy. Doses greater than 0.4 mmol/kg certainly should not be used, although our series reveals that nephrotoxic effects may occur with a dose of 0.27 mmol/kg. Despite this, gadolinium-based contrast agents appear to be approximately 20 times safer than iodinated agents in patients with renal compromise.

## REFERENCES

1. Tombach B, Bremer C, Reimer P, Kisters K, Schaefer RM, Geens V, et al. Renal tolerance of a neutral gadolinium chelate (gadobutrol) in patients with chronic renal failure: results of a randomized study. *Radiology* 2001;218:651-7.
2. Kaufman JA, Geller SC, Waltman AC. Renal insufficiency: gadopentetate dimeglumine as a radiographic contrast agent during peripheral vascular interventional procedures. *Radiology* 1996;198:579-81.
3. Prince MR, Arnoldus C, Frisoli JK. Nephrotoxicity of high-dose gadolinium compared with iodinated contrast. *J Magn Reson Imag* 1996;6:162-6.
4. Weissleder R. Can gadolinium be safely given in renal failure? *AJR Am J Roentgenol* 1996;167:278-9.
5. Schenker MP, Solomon JA, Roberts DA. Gadolinium arteriography complicated by acute pancreatitis and acute renal failure. *J Vasc Intervent Radiol* 2001;12:393.
6. Gemery J, Idelson B, Reid S, Yucel EK, Pagan-Marin H, Ali S, et al. Acute renal failure after arteriography with a gadolinium-based contrast agent. *AJR Am J Roentgenol* 1998;171:1277-8.
7. Deray G, Bellin MF, Baumelou B, Rey JP, Boulechfar H, Grellet J, et al. Renal tolerance of the paramagnetic contrast medium Gd-DOTA in patients with chronic renal failure. *Am J Nephrol* 1990;10:522-3.
8. Berns AS. Nephrotoxicity of contrast media. *Kidney Int* 1989;36:730-40.
9. Solomon R. Contrast-medium-induced acute renal failure. *Kidney Int* 1998;53:230-42.
10. Stevens MA, McCullough PA, Tobin KJ, Speck JP, Westveer DC, Guido-Allen DA, et al. A prospective randomized trial of prevention measures for contrast nephropathy: results of the PRINCE study. *J Am Coll Cardiol* 1993;33:403-11.
11. Tepel M, van der Giet M, Schwarzfeld C, Laufer U, Liermann D, Zidek W. Prevention of radiographic-contrast-agent-induced reductions in renal function by acetylcysteine. *N Engl J Med* 2000;343:180-4.
12. Kien ND, Moore PG, Jaffe RS. Cardiovascular function during induced hypotension by fenoldopam or sodium nitroprusside in anesthetized dogs. *Anesth Analg* 1992;74:72-8.
13. Velazquez OC, Baum RA, Carpenter JP. Magnetic resonance imaging and angiography. In: Rutherford RB, ed. *Vascular surgery*, 5th ed. Philadelphia, Pa: Saunders; 2000. p 269-285.
14. Schering (Pty) Ltd (Reg No: 64/09072/07) Subsidiary of Schering AG Germany. Magnevist Package Insert. 7-24-1998. Randjespark Midrand 1685.
15. Townsend RR, Cohen DL, Katholi R, Swan SK, Davies BE, Bensen K, et al. Safety of intravenous gadolinium (Gd-BOPTA) infusion in patients with renal insufficiency. *Am J Kidney Dis* 2000;36:1207-12.
16. Morasch MD, Collins J, Pereles FS, Carr JC, Eskandari MK, Pearce WH, et al. Lower extremity stepping-table magnetic resonance angiography with multilevel contrast timing and segmented contrast infusion. *J Vasc Surg* 2003;37:62-71.
17. Carpenter JP, Baum RA, Holland GA, Barker CF. Peripheral vascular surgery with magnetic resonance angiography as the sole preoperative imaging modality. *J Vasc Surg* 1994;20:861-71.
18. Carpenter JP, Owen RS, Baum RA, Cope C, Barker CF, Berkowitz HD, et al. Magnetic resonance angiography of peripheral runoff vessels. *J Vasc Surg* 1992;16:807-15.
19. Owen RS, Carpenter JP, Baum RA, Perloff LJ, Cope C. Magnetic resonance imaging of angiographically occult runoff vessels in peripheral arterial occlusive disease. *N Engl J Med* 1992;326:1577-81.
20. Spinosa DJ, Matsumoto AH, Hagspiel KD, Angle JF, Hartwell GD. Gadolinium-based contrast agents in angiography and interventional radiology. *AJR Am J Roentgenol* 1999;173:1403-9.
21. Adverse reactions to gadolinium-based contrast media. In: King BF, Segal AJ, Berg GR, editors. *Manual on contrast media*. 4th ed. Reston (VA): American College of Radiology; 1998. p 27-9.

Submitted Dec 10, 2002; accepted Feb 5, 2003.